

# Trastuzumab Deruxtecan (T-Dxd) Combined With Local Therapy For Treatment Of HR+/HER2+ Metastatic Breast Cancer With Liver And Distant Lymph Node Involvement: A Case Report

Yao Song, Hualing Wu, Yan Huang and Qing Lin\*

Department of Radiation Oncology, Tenth People's Hospital Affiliated to Tongji University, Shanghai 200072, China

**\*Corresponding author:**

Qing Lin,

Department of Radiation Oncology, Tenth People's Hospital Affiliated to Tongji University, Shanghai 200072, China

**Received Date:** 05 Dec 2024

**Accepted Date:** 14 Dec 2024

**Published Date:** 20 Dec 2024

**Citation:**

Qing Lin. Trastuzumab Deruxtecan (T-Dxd) Combined With Local Therapy For Treatment Of HR+/HER2+ Metastatic Breast Cancer With Liver And Distant Lymph Node Involvement: A Case Report. *Annals of Clinical and Medical Case Reports* 2024.

## 1. Abstract

Breast cancer is the most prevalent cancer among women globally. With in breast cancer, the HR+/HER2+ subtype is particularly notable among luminal subtypes, as it shows resistance to both endocrine and anti-HER2 therapies. This is especially true for cases with local visceral metastasis, where the necessity of adding local therapy remains a topic of debate. This report discusses a case involving a patient with HR+/HER2+ breast cancer and local visceral metastasis who has achieved long-term progression-free survival (PFS) and overall survival after receiving a treatment plan that included local therapy and T-Dxd, but did not involve enough endocrine therapy.

## 2. Introduction

Breast cancer is the leading cancer in women, and advancements in anti-HER2 targeted therapies have improved patient survival rates, particularly for those with HER2-positive HR-positive breast cancer. Approximately 15%-20% of breast cancers are HER2-positive, and nearly half of these also express hormone receptors (HRs), such as estrogen receptor (ER+) and/or progesterone receptor (PR+) [2,3]. The HR+/HER2+ subtype exhibits distinct clinical characteristics, physiological behaviors, and

treatment responses compared to HER2-overexpressing or HR+HER2- breast cancers. Patients with HR+/HER2+ breast cancer face an increasing risk of recurrence after anti-HER2 treatment due to the interplay between HER2 and estrogen receptor (ER) pathways, which can lead to resistance against anti-HER2 drugs or endocrine therapies. Although research over the past two decades has highlighted the importance of maximizing HER2 blockade to enhance survival, effective clinical strategies for managing HR+/HER2+ metastatic breast cancer (MBC) remain challenging. The emergence of antibody-drug conjugates (ADCs) has sparked debate over the necessity of endocrine therapy for HR+/HER2+ MBC patients, making it crucial to optimize treatment for this specific subtype [5]. Regarding local metastasis in breast cancer, some studies suggest that combining chemotherapy with local therapy can improve local control (LC) for MBC [6]. However, results from the NRG-BR002 clinical trial indicated that local therapy may not significantly impact MBC treatment [7], leading to ongoing discussions about its role in therapy. Herein, we present a case of breast cancer with HR+/HER+ multiple local metastasis who achieved the long-term stable survival with the T-Dxd and local therapy without endocrine therapy. This case highlights the potential for extending survival in patients with metastatic HR+/HER2+ breast cancer.

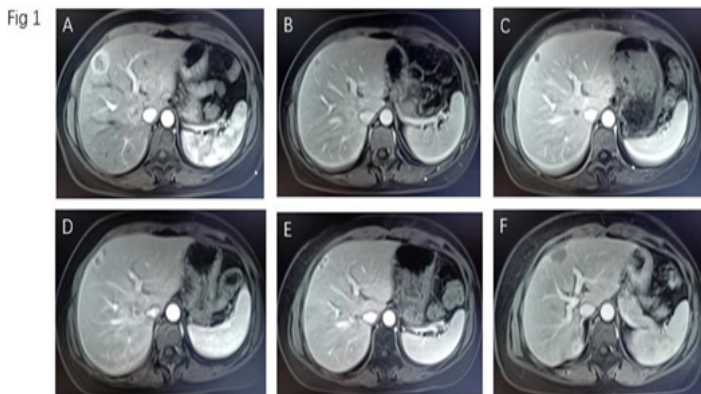
## 3. Case Presentation

The case involves a 43-years-old female, who was initially diagnosed with left breast cancer in July 2018 through fine needle aspiration cytology (FNAC), which revealed dysplastic cells consistent with ductal carcinoma, and imaging studies showed no distant organ metastasis. On July 12, 2018, the patient underwent a modified radical mastectomy for breast cancer, with histopathological analysis confirming a diagnosis of grade III invasive ductal carcinoma (IDC). The tumor was measured at 3.0 cm x 2.5 cm x 1.9 cm, and lymph node metastasis was found in 7 out of 11 nodes. The tumor was estrogen receptor positive (ER+) and progesterone receptor negative (PR-), and it tested positive for HER2. The surgical margins were clear. Following surgery, the patient received adjuvant chemotherapy, which included four cycles of adriamycin and cyclophosphamide, followed by four cycles of weekly paclitaxel and trastuzumab from July 2018 to January 2019. Maintenance therapy with trastuzumab continued for two months, and the patient also received radiation and endocrine therapy starting in January 2019. In March 2019, an MRI scan showed metastasis in the liver (segments S4 and S7). A fine needle aspiration cytology (FNAC) in April confirmed that the liver metastasis was from invasive breast cancer, with the tumor showing both

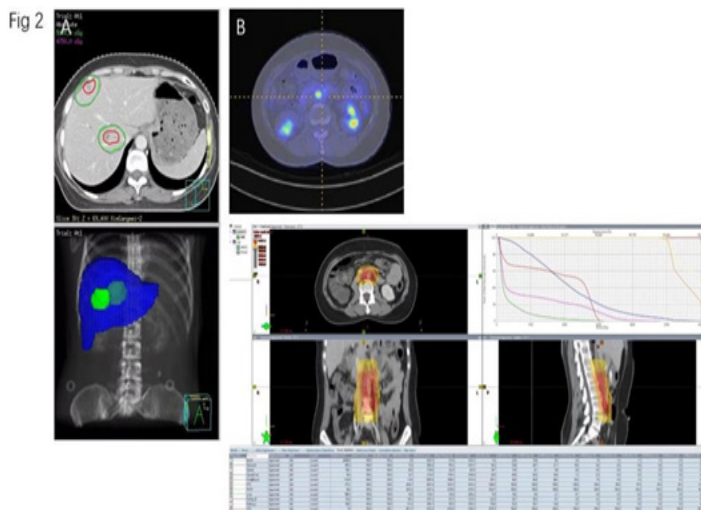
# Annals of Clinical and Medical Case Reports

estrogen and progesterone receptors (ER+ and PR+), and it was HER2 positive. The treatment plan was switched to trastuzumab+ paclitaxel +pertuzumab (TPH), but by July 2019, an MRI indicated that the liver tumor had progressed (Figure 1 A, B). The treatment was then changed to a combination of pyrotinib, capecitabine, anastrozole, and goserelin, which stabilized the tumor for a year. In August 2020, an MRI showed further progression of the liver tumor, and CA153 levels increased (Figure 1 C-E).

**Figure 1:** The liver MRI scan for patient in different time point. (A) 20190717 (B) 20191016 (C) 20200109 (D) 20200826 (E)20201016 (F)20210917



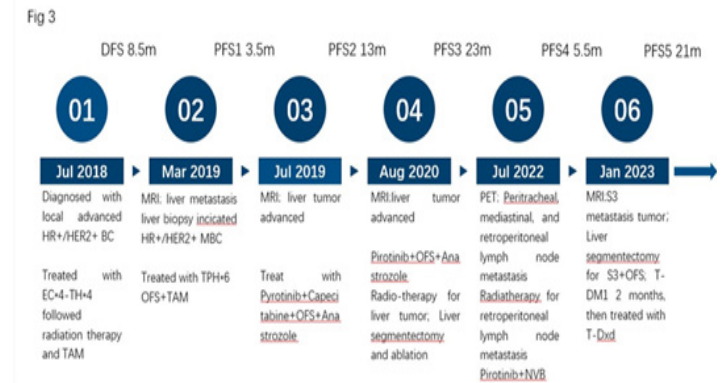Radiation therapy was administered to the liver metastasis, delivering 50Gy over 10 fractions from September 2-7, alongside pyrotinib and anastrozole with goserelin (Figure 2 A). In December 2020, a liver excision and ablation of the lesion were performed while continuing treatment with pyrotinib and anastrozole with goserelin, with histopathology showing ER+, PR+, and HER2+. In July 2022, a PET-CT scan revealed slightly enlarged lymph nodes on the right side of the trachea and new metabolic activity in mediastinal and retroperitoneal lymph nodes. CA125 was measured at 44.9 U/ml and CEA at 16.1 ng/ml. Radiation therapy was conducted for the retroperitoneal lymph nodes, in conjunction with navelbine and pyrotinib (Figure 2 B).



**Figure 2:** The local treatment for patient. (A) The radiotherapy plan figure for liver metastasis treatment in 20200902; (B) The radiotherapy plan figure for posterior peritoneal lymph node metastasis treatment in 20220810.

In January 2023, an MRI indicated a new tumor in liver segment S3, confirmed by PET-CT. A liver segmentectomy was performed, with pathology results showing ER+, PR-, and HER2+. The patient was treated with OFS and TDM1, and in July 2023, the medication was switched to T-Dxd plus oophorectomy. By September, MRI and CT scans indicated a good response in the lymph nodes, with no new lesions developing, the total timeline of treatment for breast cancer patients as shown in (Figure 3).

**Figure 3:** Timeline of treatment for breast cancer patients.



## 4. Discussion

This case report details the patient's first recurrence of local liver metastasis, following NCCN and CSCO guidelines for treating HER2-positive metastatic breast cancer with first and second-line therapies, along with endocrine therapy. The first treatment resulted in stable disease for only 3.5 months, while the second achieved stable disease for a year. Upon the third recurrence, imaging revealed only local liver metastasis, leading to consideration of local therapy due to the short recurrence interval and oligometastatic nature of the breast cancer. Millen JCA [8] noted that patients with liver metastases who received chemotherapy combined with liver radiation (LR) experienced better overall survival (OS) compared to those who received chemotherapy alone, both in estrogen receptor-positive (ER+) and triple-negative breast cancer cases. Ciro Franzese et al. [9] found that combining systemic therapy with liver multidisciplinary team (MDT) approaches in oligometastatic breast cancer led to sustained disease control in a significant number of patients. Additionally, several clinical trials have shown that in HR+/HER2+ metastatic breast cancer, the combination of tyrosine kinase inhibitors (TKIs) with endocrine therapy yielded disease-free survival (DFS) and OS rates comparable to those achieved with chemotherapy combined with targeted therapy and endocrine therapy, suggesting this could be a viable treatment option for visceral metastases [10-12]. Based on this evidence, we opted for a combination of pirotinib, ovarian function suppression (OFS), and

# Annals of Clinical and Medical Case Reports

anastrozole along with local liver radiation therapy and surgery, resulting in a progression-free survival (PFS) of nearly two years.

Subsequently, the patient developed new metastases in the lymph nodes and liver. We introduced local radiotherapy for the lymph nodes and surgery for the liver, and from June 2023, we also added OFS and antibody-drug conjugate (ADC) therapy with T-DXd. As of now, the patient has not experienced any new tumors, leading to a PFS of 20 months. In patients with HER2-positive metastatic breast cancer, the failure of trastuzumab therapy was noted, and the PHENIX and PHOEBE clinical trials showed that the PFS for pirotinib combined with capecitabine exceeded 10 months, whereas the PFS for lapatinib plus capecitabine was only 5.6 months, and 4.1 months for the capecitabine-only group [13,14]. The EMILIA trial reported a PFS of 9.6 months for T-DM1, compared to just 6.4 months for lapatinib plus capecitabine [15]. The PHEREXA trial found no significant difference in PFS between the dual HER2-targeted therapy and the standard treatment [16]. The Destiny Breast trial evaluated T-DXd and T-DM1 across phases I to III, with DB03 indicating a PFS of 28.8 months for the T-DXd group versus 6.8 months for the T-DM1 group. After five years of follow-up, the PFS2 was 45.2 months for T-DXd compared to 23.1 months for T-DM1 (95% CI, 17.8-29.7 months; HR, 0.53; 95% CI, 0.41-0.68) [17-20].

Therefore, we chose T-DXd for treatment when the patient experienced her fifth recurrence. Although she had HR+/HER2+ metastatic breast cancer, there is still a lack of clinical evidence regarding the effectiveness of combining endocrine therapy with anti-HER2 therapy to improve PFS and OS. The DETECT V trial indicated that in HR+/HER2+ metastatic breast cancer, dual HER2-targeted therapy with trastuzumab and pertuzumab, combined with endocrine therapy and ribociclib, or chemotherapy followed by maintenance therapy with trastuzumab, pertuzumab, endocrine therapy, and ribociclib, showed no significant differences in PFS and OS. While the safety of endocrine therapy and ADCs was reported to be tolerable, their impact remains unreported [21]. In Destiny breast-03, the complete response (CR) reached 21%. However, the subtype analysis revealed that the CR achieved by T-DXd in the HR+ group was not significantly higher than in the HR- group. There was no data to support that the development was linked to HR status, and combining T-DXd with a CDK4/6 inhibitor could lead to hematotoxicity. Therefore, we did not enhance the endocrine therapy combination for T-DXd treatment. Nevertheless, the patient is currently experiencing grade II hematotoxicity, and T-DXd treatment is still ongoing.

## References

- Grada MS, Senkus E. Anti-HER2 Drugs for the Treatment of Advanced HER2 Positive Breast Cancer. *Curr Treat Options Oncol*. 2023; 24(11): 1633-1650. doi: 10.1007/s11864-023-01137-5.
- Konecny G, Pauletti G, Pegram M, et al. Quantitative association between HER-2/neu and steroid hormone receptors in hormone receptor-positive primary breast cancer. *JNCI J Nat Cancer Inst* 2003; 95(2): 142–53. <https://doi.org/10.1093/jnci/95.2.142>.
- Pereira B, Chin SF, Rueda OM, et al. The somatic mutation profiles of 2,433 breast cancers refine their genomic and transcriptomic landscapes. *Nat Commun* 2016; 7(1): 11479. <https://doi.org/10.1038/ncomms11479>.
- Shou J, Massarweh S, Osborne CK, et al. Mechanisms of tamoxifen resistance: increased estrogen receptor-HER2/neu cross-talk in ER/HER2-positive breast cancer. *JNCI J Nat Cancer Inst* 2004; 96(12): 926–35. <https://doi.org/10.1093/jnci/djh166>
- Boscolo BL, Trapani D, Nicolò E, Valenza C, Guidi L, Belli C. et.al. The evolving landscape of metastatic HER2-positive, hormone receptor-positive Breast Cancer. *Cancer Treat Rev*. 2024: 128: 102761. doi: 10.1016/j.ctrv.2024.102761. Epub 2024 May 16.
- Sofi AA, Mohamed I, Koumaya M, Kamaluddin Z. Local therapy in metastatic breast cancer is associated with improved survival. *Am J Ther*, 2013; 20(5): 487-92. doi: 10.1097/MJT.0b013e31822119c5.
- Chmura SJ, Winter KA, Woodward WA, Borges VF, Salama JK, Hallaq HA, et.al. NRG-BR002: A phase IIR/III trial of standard of care systemic therapy with or without stereotactic body radiotherapy (SBRT) and/or surgical resection (SR) for newly oligometastatic breast cancer (NCT02364557). *Journal of Clinical Oncology*, Volume 40, Number 16\_suppl. [https://doi.org/10.1200/JCO.2022.40.16\\_suppl.1007](https://doi.org/10.1200/JCO.2022.40.16_suppl.1007)
- Millen JCA, Hofmann A, Neto JWM, Rose J, Macedo FI. Evolving role of liver resection in selected patients with metastatic breast cancer. *J Surg Res* . 2021 Mar; 259: 363-371. doi: 10.1016/j.jss.2020.09.022.
- Franzese C, Comito T, Viganò L, Pedicini V, Franceschini D, Clerici E. et.al. Liver Metastases-directed Therapy in the Management of Oligometastatic Breast Cancer. *Clin Breast Cancer* . 2020 Dec; 20(6): 480-486. doi: 10.1016/j.clbc.2020.05.006.
- Swain SM, Miles D, Kim SB, Im YH, Im SA, Semiglazov V. et. al. Pertuzumab, trastuzumab, and docetaxel for HER2-positive metastatic breast cancer (CLEOPATRA): end-of-study results from a double-blind, randomised, placebo- controlled, phase 3 study. *Lancet Oncol*, 2020 Apr; 21(4): 519-530. doi: 10.1016/S1470-2045(19)30863-0.
- Johnston SRD, Hegg R, Im SA, et al. Phase III, Randomized Study of Dual Human Epidermal Growth Factor Receptor 2 (HER2) Blockade With Lapatinib Plus Trastuzumab in Combination With an Aromatase Inhibitor in Postmenopausal Women With HER2-Positive, Hormone Receptor-Positive Metastatic Breast Cancer: Updated Results of ALTERNATIVE [published online ahead of print, 2020 Aug 21]. *J Clin Oncol*. 2020; JCO2001894. doi:10.1200/JCO.20.01894
- Arpino G, de la Haba-Rodríguez J, Ferrero JM, et al. Pertuzumab, trastuzumab, and an aromatase inhibitor for HER2-positive and hormone receptor-positive metastatic/locally advanced breast cancer: PERTAIN final analysis. *Clin Cancer Res*. 2023. 10.1158/1078-0432.CCR-22-1092.
- Xu B, Yan M, Ma F, Hu X, Feng J, Ouyang Q. et.al. Pyrotinib plus capecitabine versus lapatinib plus capecitabine for the treatment of

- HER2-positive metastatic breast cancer (PHOEBE): a multicentre, open-label, randomised, controlled, phase 3 trial. *Lancet Oncol*, 2021; 22(3): 351-360. doi: 10.1016/S1470-2045(20)30702-6.
14. Yan M, Bian L, Hu X, et al. Pyrotinib plus capecitabine for human epidermal growth factor receptor 2-positive metastatic breast cancer after trastuzumab and taxanes (PHENIX): a randomized, double-blind, placebo-controlled Phase 3 study. *Transl Breast Cancer Res*. 2020; 1: 13. doi:10.21037/tbcr-20-25
  15. Diéras V, Miles D, Verma S, Pegram M, Welslau M, Baselga J. et.al. Trastuzumab emtansine versus capecitabine plus lapatinib in patients with previously treated HER2-positive advanced breast cancer (EMILIA): a descriptive analysis of final overall survival results from a randomised, open-label, phase 3 trial. *Lancet Oncol*, 2017; 18(6): 732-742. doi: 10.1016/S1470-2045(17)30312-1.
  16. Urruticoechea A, Urruticoechea A, Rizwanullah M, et al. PHEREXA: A phase III study of trastuzumab (H) + capecitabine (X) ± pertuzumab (P) for patients (pts) who progressed during/after one line of H-based therapy in the HER2-positive metastatic breast cancer (MBC) setting.[J].*Journal of Clinical Oncology*, 2016; 34(15\_suppl): 504-504.DOI:10.1200/JCO.2016.34.15\_SUPPL.504.
  17. Modi S , Saura C , Yamashita T ,et al.Abstract PD3-06: Updated results from DESTINY-breast01, a phase 2 trial of trastuzumab deruxtecan (T-DXd ) in HER2 positive metastatic breast cancer[C]// Abstracts: 2020 San Antonio Breast Cancer Virtual Symposium; December 8-11, 2020; San Antonio, Texas.2021.DOI:10.1158/1538-7445.SABCS20-PD3-06.
  18. André F, Hee Park Y, Kim S-B, et al. Trastuzumab deruxtecan versus treatment of physician's choice in patients with HER2-positive metastatic breast cancer (DESTINY-Breast02): a randomised, open-label, multicentre, phase 3 trial[J]. *Lancet*. 2023 27; 401(10390): 1773-1785. doi: 10.1016/S0140-6736(23)00725-0.
  19. Hurvitz SA, Hegg R, Chung WP, Im SA, Jacot W, Ganju V. et. al. Trastuzumab deruxtecan versus trastuzumab emtansine in patients with HER2-positive metastatic breast cancer: updated results from DESTINY-Breast03, a randomised, open-label, phase 3 trial. *Lancet*. 2023 Jan 14; 401(10371): 105-117. doi: 10.1016/S0140-6736(22)02420-5. Epub 2022 Dec 7
  20. Hamilton E, Hurvitz S, Im S, et al. Trastuzumab deruxtecan (T-DXd) vs trastuzumab emtansine (T-DM1) in patients (pts) with HER2+ metastatic breast cancer (mBC): Updated survival results of DESTINY-Breast03. 2024 ASCO. 1025.
  21. Harbeck N, Nitz UA, Christgen M, et al. De-escalated neoadjuvant trastuzumab- emtansine with or without endocrine therapy versus trastuzumab with endocrine therapy in HR+/HER2+ early breast cancer: 5-year survival in the WSG-ADAPT-TP Trial. *J Clin Oncol*. 2023. 10.1200/JCO.22.01816.