

Texture Analysis of Quantitative ADC Maps to Differentiate Low from High Grade Glioma

Shesnia Salim* and Padikkalakandy Cheriya
First Hospital of Dalian medical University, China

*Corresponding author:

Shesnia Salim,
First Hospital of Dalian medical
University, China, China,
E-mail: dr_rishalreshin_md@hotmail.com

Received: 09 Apr 2022
Accepted: 02 May 2022
Published: 06 May 2022
J Short Name: ACMCR

Copyright:

©2022 Shesnia Salim. This is an open access article distributed under the terms of the Creative Commons Attribution License, which permits unrestricted use, distribution, and build upon your work non-commercially.

Citation:

Shesnia Salim, Whole Tumor Volume Based Histogram Analysis of ADC for Differentiating between low Grade II and III Glioma. Ann Clin Med Case Rep. 2022; V9(2): 1-5

1. Introduction

Accurate discrimination between high grade gliomas (HGG) and metastatic brain tumor (MET) using noninvasive imaging is essential for selecting appropriate surgical and radiotherapy treatments and for determining the treatment response.

2. Brain Tumors

Any uncontrolled growth of abnormal cells is called a tumor and when located within the brain they are known as brain tumors. They are categorized into Primary and Secondary brain tumors in which Primary brain tumors are tumors that arise from the cells, the meninges or neurons in the brain and Secondary tumors are those that do not initiate in the brain. The most common primary ones are Gliomas and Meningiomas. Gliomas are derived from glial cells such as astrocytes, oligodendrocytes, and ependymal cells. World Health Organization (WHO) classifies gliomas into four categories on the basis of their histologic features and malignancies.

3. DWI and ADC

Brain diagnostic assay represents the gold customary for histopathological diagnosing, that relies on nuclear pleomorphism, mitotic activity, physiological condition, epithelial tissue cell multiplication and presence of gangrene [1]. This is often more and more challenged by new non-invasive advanced techniques and analysis into extra sequences to enhance imaging diagnostic accuracy. Image non-uniformity quantification and a lot of correct non-invasive imaging techniques might impact patient management by permitting a lot of tailored and customized management. Discovering new ways which utilizes pictures that exist before

hand so that it has the ability to not only raise the standard of diagnoses but also in addition to it, utilize scarce attention resources in the most optimal manner. Owing to its multi-parametric approach, MRI is visually a lot more heterogeneous than CT and should be a strong platform to quantify neoplasm non-uniformity with ease. MR images contain in a great amount of information on the texture properties which maybe useful for diagnosis and treatment in clinical settings. However, MRI is not capable of producing information at the microscopic level to be evaluated visually due to its basic limitations in resolution qualities. Although, textural changes maybe generated in MR images corresponding to the histological changes which can be easily quantified using texture analysis.

There seems to be an inverse correlation between Apparent Diffusion Coefficient (ADC) And cellularity in tumors which is measured from Diffusion Weighted Images (DWI) or DTI [2,3]. Similarly, the use of ADC in differentiating between PCL, HGG and METS have been demonstrated in previous studies [4,5]. The role of diffusion-weighted (DW) magnetic resonance (MR) imaging with Quantitative apparent diffusion coefficients (ADCs) in the pretreatment evaluation of glioma grade has been investigated in various studies [6-11].

4. Texture Analysis

Texture is a property that describes pictorial and volumetric aspects of an object two dimensionally and three-dimensionally respectively. Both in nature and man-made objects, texture is observed and detected qualitatively by sense of touch and vision and described as fine, coarse, smooth, irregular or lineated depending upon our perception. [12] However, there exists a limitation in the

ability of human vision to detect and differentiate complex textures [13]. Numerous parameters may be used to quantitatively define and analyse texture using various techniques of calculation. [14] But unfortunately, these methods also are unable to detect textural differences above the limits of human ability [15].

5. Method

Fourteen patients with low grade glioma and 47 patients with high grade glioma were enrolled in this retrospective study in which tumor grades were pathologically confirmed. All the participants underwent DWI on a 3.0T whole body scanner. ROIs that contained the entire tumor and peripheral edema were drawn in each slice of the ADC maps. Then texture voxel wise measurements of the entire tumor volume were obtained. Texture parameters including the following were recorded.

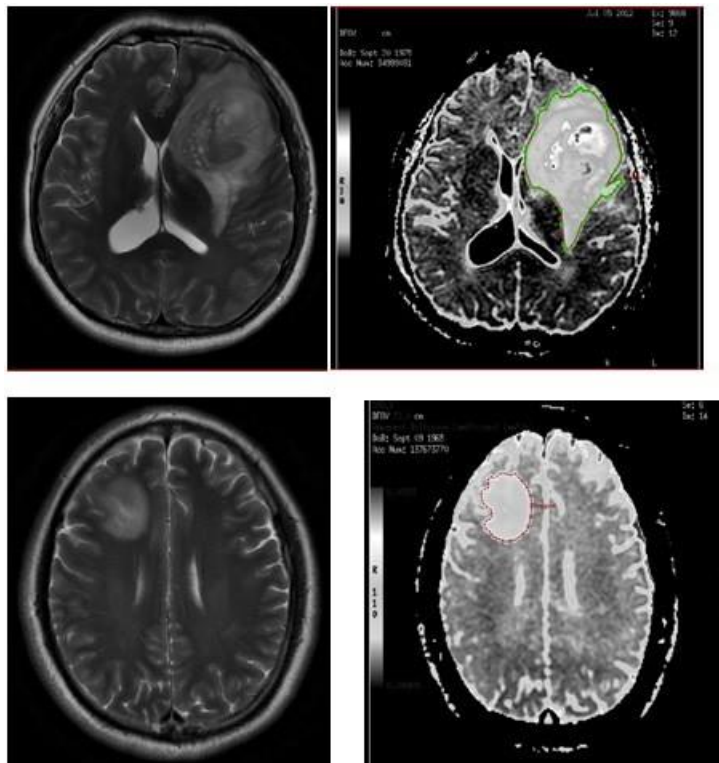
1. First-order and histogram parameters include min intensity, max intensity, mean value, median intensity, the 10th,25th,50th,75th and 90th percentiles, range, voxel number, std deviation, variance, relative deviation, mean deviation, skewness, kurtosis and uniformity.
- 2.Gray level co-occurrence matrix parameters consist of energy, entropy, inertia, correlation, inverse difference moment.
- 3.Gray level run length maxia parameters contains long run emphasis, short run emphasis, grey level nonuniformity, run length nonuniformity.

The obtained parameters were compared between groups through the SPSS 18.0. Using logistic regression analysis the independent risk factors and joint variables were obtained, receiver operating characteristic (ROC) test was used to assess the ability of independent risk factors and joint variable between low and high grade gli-

oma. All statistical results were $P < 0.05$ as statistically significant.

6. Results

The ADC map of typical cases of low and high grade glioma are shown in Figure 1. The texture parameters of low and high grade glioma and comparison results are summarized in Table 1. It can be seen that min intensity, max intensity, median intensity, mean value, the 10th, 25th, 50th, 75th, 90th percentiles, skewness, uniformity, correlation, inverse difference moment, short run emphasis are decreased in high grade than low grade, and on the contrary, range, voxel number, std deviation, variance, relative deviation, mean deviation, kurtosis, energy, entropy, inertia, long run emphasis, grey level nonuniformity, run length nonuniformity are increased. Among all, min intensity ($p=0.041$), 10th percentiles ($p=0.003$), voxel number ($p=0.0001$), skewness ($p=0.001$), entropy ($p=0.001$), inverse difference moment ($p=0.002$), long run emphasis ($p=0.005$), short run emphasis ($p=0.012$), run length nonuniformity ($p=0.000$), showed significant difference between two groups. Entering min intensity, 10th percentiles, voxel number, skewness, entropy, inverse difference moment, long run emphasis, short run emphasis, run length nonuniformity into logistic regression analysis, using step-by-step regression method it was obtained that skewness, entropy and long run emphasis are the independent risk factors, the prediction accuracy of logistic regression model is 86.9%, the regression coefficient, OR value and p value of them are shown in Table 2. Combining all independent risk factors into a joint variable, the ROC test showed that skewness, entropy, long run emphasis and joint variable feature significant difference between two groups (Figure 2), The AUC, cutoff value, sensitivity and specificity of the parameters are summarized in Table 3, and the best parameter is joint variable, the AUC is 0.956.



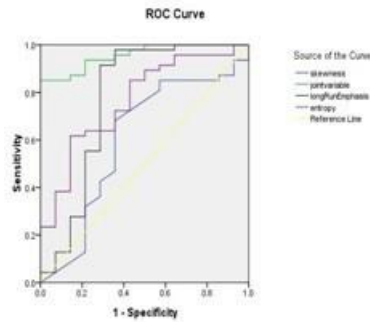


Figure a-b: WHO grade IV,T2WI(fig.a)shows mix signal intensity in tumor,necrotic area can be seen,with edema signal. In ADC maps(fig.b) ROI was drawn including the entire tumor and peripheral edema. Fig c-d, WHO grade II show uniform slightly higher intensity on T2WI(fig.c). In ADC maps(fig.d), ROI was drawn along the border of uniform mass. Fig.e is the ROC curve of skewness, entropy,long run emphasis and a joint variable of them,the AUC of them is 0.956, 0.774,0.766,0.602.

Table 1: Texture parameters of ADC signal values between low and high grade glioma.

ADC signal value texture analysis parameter	Low grade(n=14)	High grade(n=47)	p value
Min intensity	(1.22±0.42)×102	(0.85±0.59)×102	0.041 [#]
Max intensity	(2.32±0.09)×102	(2.31±0.09)×102	0.938
Median intensity	(1.93±0.06)×102	(1.92±0.03)×102	0.778
Mean value	(1.93±0.06)×102	(1.89±0.07)×102	0.460
10th percentiles	(1.83±0.04)×102	(1.58±0.37)×102	0.003 [#]
25th percentiles	(1.87±0.07)×102	(1.84±0.16)×102	0.231
50th percentiles	(1.94±0.05)×102	(1.93±0.04)×102	0.680
75th percentiles	(1.94±0.07)×102	(1.94±0.04)×102	0.879
90th percentiles	(2.01±0.10)×102	(2.01±0.08)×102	0.961
Range	(1.11±0.47)×102	(1.46±0.62)×102	0.060
Voxel number*	(5.24±2.48)×106	(1.26±0.89) ×107	0.001 [#]
Std deviation	(1.29±1.08)×101	(1.95±1.11)×101	0.208
Variance*	(1.18±0.27)×102	(2.15±0.98)×102	0.208
Relative deviation	(6.17±0.64)×101	(6.61±0.97)×101	0.460
Mean deviation	(1.10±0.88) ×104	(2.49±1.07) ×104	0.122
Skewness*	-0.95±-1.53	-3.05±-5.81	0.001 [#]
Kurtosis*	6.76±3.56	8.65±4.36	0.929
Uniformity	0.93±0.06	0.92±0.85	0.208
Energy *	0.09±0.03	0.12±0.06	0.438
Entropy	3.40±0.97	4.40±0.94	0.001 [#]
Inertia*	2.78±1.32	4.51±2.43	0.361
Correlation*	0.18±0.04	0.11±0.06	0.395
Inverse difference moment	0.72±0.12	0.62±0.10	0.002 [#]
Long run emphasis*	0.99±0.95	0.99±0.97	0.005 [#]
Short run emphasis *	1.07±1.01	1.03±1.00	0.012 [#]
Grey level nonuniformity*	(1.41±0.45) ×103	(2.28±0.95) ×103	0.294
Run length nonuniformity	(2.72±1.95) ×104	(5.67±3.94) ×104	0.000 [#]

Note: *on behalf of the nonnormal diatribution, representation with median value±interquartile.[#]

Table 2: Binary logistic regression.

Texture analysis parameter	Regression coefficient	OR value (95%CI)	p value
Skewness	-1.0017	0.362(0.123,0.062)	0.010
Entropy	1.887	6.598(5.322,32.928)	0.021
Long run emphasis	11.551	1.039(1.004,1.108)	0.013

Table 3: ADC signal value texture parameters diagnostic ability.

ADC signal value texture parameters	AUC	cutoff value	sensitivity	specificity
Joint variance	0.956	0.804	85.1%	100%
Long run emphasis	0.774	0.990	95.7%	92.9%
Entropy	0.766	4.069	61.7%	85.7%
Skewness	0.602	-1.549	68.1%	64.3%

7. Discussion and Conclusion

Texture analysis is a new image post-processing technique, reflect intrinsic properties include gray level statistical information, space and structure information, besides, contains the contact with surrounding environment of a given voxel [3]. Different grade glioma has different heterogeneity, tumor parenchyma and cystic, necrosis and hemorrhage area shows different signal on ADC maps, cause different texture, so as to realize quantitative analysis. In this study, min intensity and 10th percentiles showed significant difference between low and high grade glioma, suggesting that ADC value in low zone is more meaningful. In other words, the lower range of ADC better reflects the progress of higher cellularity. Standard deviation shows the level of data dispersion, higher standard deviation of ADC indicates larger regions of cystic, necrosis or haemorrhage. Skewness describes the symmetry of the curve distribution. Compared with low grade, the ADC value of high grade concentrate on low zone, the center of the histogram curve was shifted to left. Entropy and inverse difference moment reflect gray level uniformity of image, showed significant difference between low and high grade glioma, illustrate that high grade glioma is more nonuniform than low grade. Run emphasis reflect direction, distance and variability of texture quantitative, the long run emphasis increase and short run emphasis decrease significantly in high grade glioma compare with low grade, illustrate that high grade contains more long run factors and less short run factors, low grade glioma contains less long run factors and more short run factors, run length nonuniformity of high grade glioma is higher too. Overall, it is seen that texture analysis of ADC signal value based on entire tumor could provide more information in differentiation of low and high grade glioma. Through logistic regression analysis we obtain skewness, entropy, long run emphasis are the independent risk factors, and joint application of them showed superior diagnostic value.

References

1. Cancer Genome Atlas Research N. Comprehensive genomic characterization defines human glioblastoma genes and core pathways. *Nature*. 2008; 455(7216): 1061-8.
2. Guo AC, Cummings TJ, Dash RC. Lymphomas and high-grade astrocytomas: comparison of water diffusibility and histologic characteristics. *Radiology*. 2002; 224(1): 177-183.
3. Yamasaki F, Kurisu K, Satoh K. Apparent diffusion coefficient of human brain tumors at MR imaging. *Radiology*. 2005; 235(3): 985-991.
4. Batra A, Tripathi RP. Atypical diffusion-weighted magnetic resonance findings in glioblastoma multiforme. *Australasian Radiology*. 2004; 48(3): 388-391.
5. Toh CH, Chen YL, Hsieh TC. Glioblastoma multiforme with diffusion-weighted magnetic resonance imaging characteristics mimicking primary brain lymphoma. Case report. *Journal of neurosurgery*. 2006; 105(1): 132-135.
6. Sugahara T, Korogi Y, Kochi M. Usefulness of diffusion-weighted MRI with echo-planar technique in the evaluation of cellularity in gliomas. *Journal of magnetic resonance imaging: JMIR*. 1999; 9(1): 53-60.
7. Murakami R, Hirai T, Kitajima M. Magnetic resonance imaging of pilocytic astrocytomas: usefulness of the minimum apparent diffusion coefficient (ADC) value for differentiation from high-grade gliomas. *Acta radiologica*. 2008; 49(4): 462-467.
8. Provenzale JM, Mukundan S, Barboriak DP. Diffusion-weighted and perfusion MR imaging for brain tumor characterization and assessment of treatment response. *Radiology*. 2006; 239(3): 632-649.
9. Tozer DJ, Jager HR, Danchaivijitr N. Apparent diffusion coefficient histograms may predict low-grade glioma subtype. *NMR in biomedicine*. 2007; 20(1): 49-57.
10. Arvinda HR, Kesavadas C, Sarma PS. Glioma grading: sensitivity, specificity, positive and negative predictive values of diffusion and perfusion imaging. *Journal of neuro-oncology*. 2009; 94(1): 87-96.

11. Lee EJ, Lee SK, Agid R. Preoperative grading of presumptive low-grade astrocytomas on MR imaging: diagnostic value of minimum apparent diffusion coefficient. *AJNR American journal of neuroradiology*. 2008; 29(10): 1872-1877.
12. Haralick RM, Shanmugam K, Dinstein I. Textural Features for Image Classification. *IEEE Transactions on Systems, Man, and Cybernetics*. 1973; SMC-3(6): 610-21.
13. Julesz B, Gilbert EN, Shepp LA. Inability of humans to discriminate between visual textures that agree in second-order statistics-revisited. *Perception*. 1973; 2(4): 391-405.
14. M Tuceryan and A K Jain. "Texture Analysis. The Handbook of Pattern Recognition and Computer Vision (2nd Edition)," World Scientific Publishing C. 1998; 207-248.
15. Harrison Lara. Clinical Applicability of MRI Texture Analysis.
16. [Doctoral thesis]. Univeristy of Tampere: Tampere University Press. 2011.