

Computerized Misinterpretation of QT Interval in 12-Lead Electrocardiogram and Its Clinical Consequences: A Case of Recurrent Syncope

Kanae Hasegawa¹, Yoshitomo Fukuoka¹, Seiko Ohno², Hiroyasu Uzui¹, Minoru Horie³ and Hiroshi Tada^{1*}

¹Department of Cardiovascular Medicine, Japan

²Department of Bioscience and Genetics, Japan

³Department of Cardiovascular Medicine, Japan

*Corresponding author:

Tada,
Department of Cardiovascular Medicine Faculty
of Medical Sciences,
Eiheiji-cho, Fukui 910-1193, Japan,
Tel: +81-776-61-8800, Fax: +81-776-61-8801,
E-mail: htada@u-fukui.ac.jp

Received: 11 Feb 2022

Accepted: 28 Feb 2022

Published: 07 Mar 2022

JShortName: ACMCR

Copyright:

©2022 Hiroshi Tada. This is an open access article distributed under the terms of the Creative Commons Attribution License, which permits unrestricted use, distribution, and build upon your work non-commercially.

Citation:

Hiroshi Tada, Computerized Misinterpretation of QT Interval in 12-Lead Electrocardiogram and Its Clinical Consequences: A Case of Recurrent Syncope. *Ann Clin Med Case Rep.* 2022; V8(13):1-5

Keywords:

Automated diagnosis; QT interval; Syncope; Long QT syndrome

1. Abstract

The diagnosis of long QT syndrome may be delayed due to absence of electrocardiogram (ECG) examination and/or QT interval misdiagnosis. We present the case of a patient who took 8 years before being diagnosed with long QT syndrome. Despite the presence of marked QT prolongation and bimodal T waves, automated ECG recording misdiagnosed the patient to be normal. The patient had recurrent syncope; however, repeat ECG examination was not performed because her initial ECG was considered normal. It is crucial in cases of syncope that multiple ECG examinations and physician assessment of findings are performed, without relying exclusively on an automated ECG diagnosis.

2. Abbreviations: ECG: Electrocardiogram; QTc: Corrected QT Interval; TdP: Torsades De Pointes

3. Introduction

Patients with cardiac syncope have increased risk of death [1], and the occurrence of “syncope” is an important indicator of arrhythmic risk [1-3]. Patients with unexplained syncope may have hidden long QT syndrome (LQTS) [2]. Although electrocardiogram (ECG) is important for the diagnosis of LQTS, the diagnosis may be delayed due to absence of ECG examination and/or difficulties of QT interval evaluation [2]. Automated ECG diagnosis has the benefit to reduce the effort of physician for ECG evaluation [4]. However, the automated ECG diagnosis are not always correct, in particular, QT interval [5]. We present the case of a patient

for whom LQTS diagnosis took 8 years. Despite the presence of marked QT prolongation and bimodal T waves, automated ECG diagnosis misdiagnosed the patient to be normal at the first syncope. The patient had recurrent syncope; however, repeat ECG examination was not performed.

4. Case Report

A 27-year-old female visited our emergency room in the middle of the night because she experienced syncope several times throughout the preceding 2 days upon waking up and when attempting walking at night. At the time of the visit, her consciousness level was clear and plasma potassium concentration was 4.0 mEq/L (normal range: 3.6–4.8 mEq/L). Her 12-lead electrocardiogram (ECG) revealed sinus rhythm (65 beats/min) and QT prolongation with low amplitude T waves (QT/QTc [intervals], 600/640 ms) (Figure 1A). Echocardiography, chest X-ray, and brain magnetic resonance imaging (MRI) findings were normal. She was admitted for follow-up due to the presence of marked QT prolongation on 12-lead ECG. Five hours after the admission, torsades de pointes (TdP) spontaneously occurred with typical initiating “short-long-short” sequences (Figure 1B) when she felt faintness. Therefore, the patient was clinically diagnosed with long QT syndrome. She had no abnormal ECG findings in past school physical examination. She had no family history of syncope, sudden death, or long QT syndrome (Figure 2A). ECGs of her mother and son showed no QT prolongation (Figure 2A). At the age of 19, the patient expe-

rienced nightmares during sleep, which were followed by convulsions and groaning. She fainted twice after waking in the morning. The patient visited a neurology clinic and underwent brain MRI, but the underlying cause remained unknown. At the age of 21, she experienced dizziness while walking or trying to get up in the morning. She experienced syncope and visited a hospital, where automated ECG diagnosis was within the normal range (Figures 3A, 3B). Brain computed tomography and electroencephalogram revealed no obvious abnormality. Therefore, the physician found no apparent cause for her syncope and she returned home. The patient continued to have episodes of syncope several times a year until she the age of 27. Throughout this period, she visited several hospitals and clinics. However, episodes of syncope due to long QT syndrome was not suspected, and the patient did not undergo another ECG examination nor was referred to a cardiologist. After admission to our hospital, the ECG recorded at the age of 21 was retrieved and re-evaluated. Her ECG revealed QT prolongation with notched T waves (Figure 3A), a finding that was

clearly abnormal (QT/QTc, 580/608ms). Genetic analysis for long QT syndrome including KCNQ1, KCNH2, SCN5A, KCNE1, and KCNE2 was performed after obtaining written informed consent from the patient. A novel frameshift variant that resulted from duplication (c. 526dupC, p.R176fsX331) in KCNH2 was identified (Figure 2B). Her mother and son, who did not have QT prolongation, did not carry the variant (Figure 2A). The patient was diagnosed with type 2 long QT syndrome. Carvedilol was initiated from 5.0 mg per day, and the dose was gradually increased. One month later, her QT interval had shortened (QT/QTc, 480/488ms), and notched T waves had disappeared (Figure 4A). Two months later, when taking 7.5mg carvedilol per day, her QT interval shortened further (QT/QTc, 460/460ms) (Figure 4B). After six months of receiving 10mg carvedilol per day, her QT interval completely normalized (QT/QTc, 450/442), and T-wave shape was no longer abnormal (Figure 4C). The patient recovered well, and no syncope recurrence was observed throughout a 3-year follow-up period.

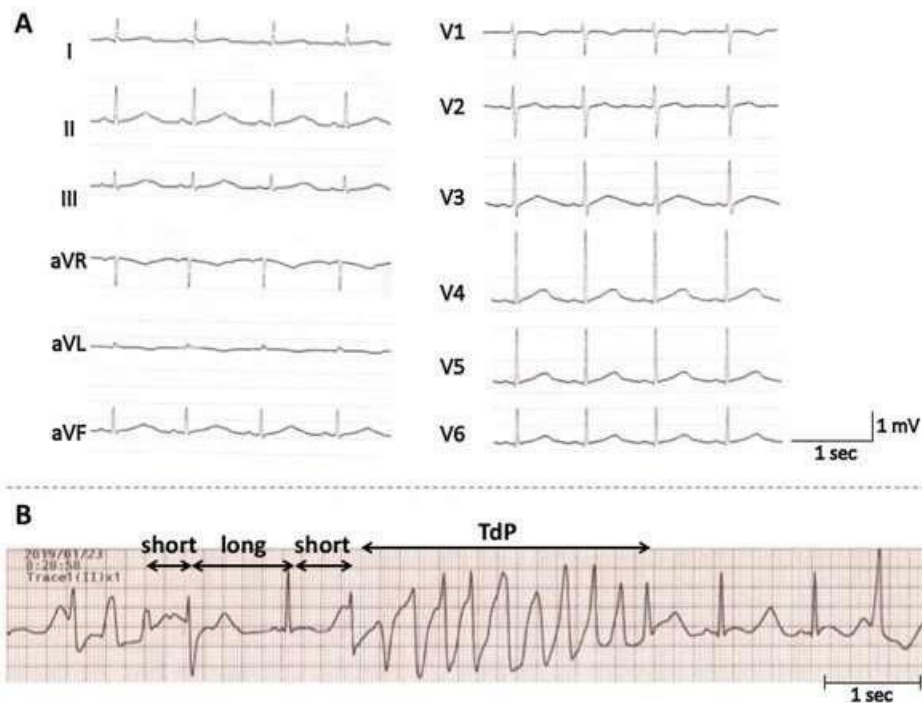


Figure 1. A) Twelve-lead electrocardiogram on admission. B) Tracings of bedside continuous single-lead ECG after admission. Torsades de pointes spontaneously occurred with typical initiating the “short-long-short” sequence.

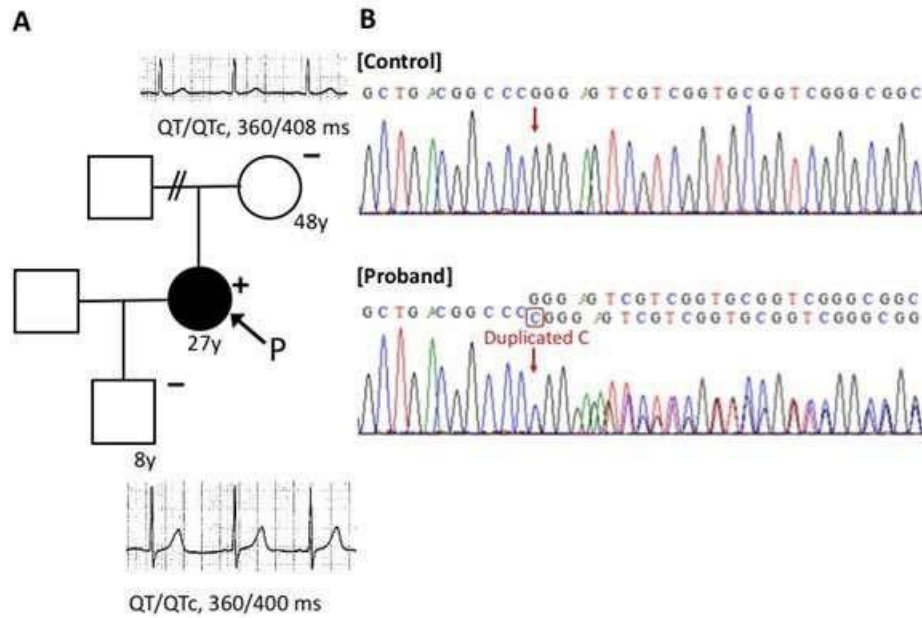


Figure 2. A) Pedigree of *KCNH2*, p.R176fsX331. Circles and squares indicate females and males, respectively. Closed symbol indicates a history of syncope. Plus signs indicate variant positive subjects, whereas minus signs indicate variant negative subjects. The black arrow indicates the proband of the family. Electrocardiograms in lead V5 of the patient's mother and son showed no QT prolongation. B) Electropherograms of *KCNH2* in control and the *KCNH2* gene variant, p.R176fsX331 (c. 526dupC), in the patient.

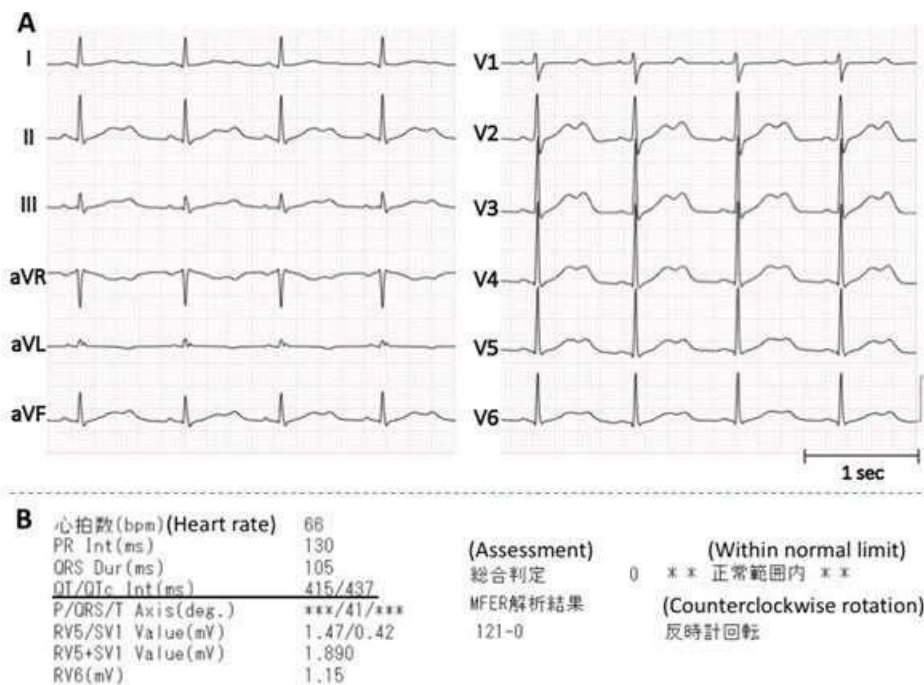


Figure 3. A) Twelve-lead electrocardiogram (ECG) recorded when the patient was aged 21 years. B) An automated diagnosis based on ECG.

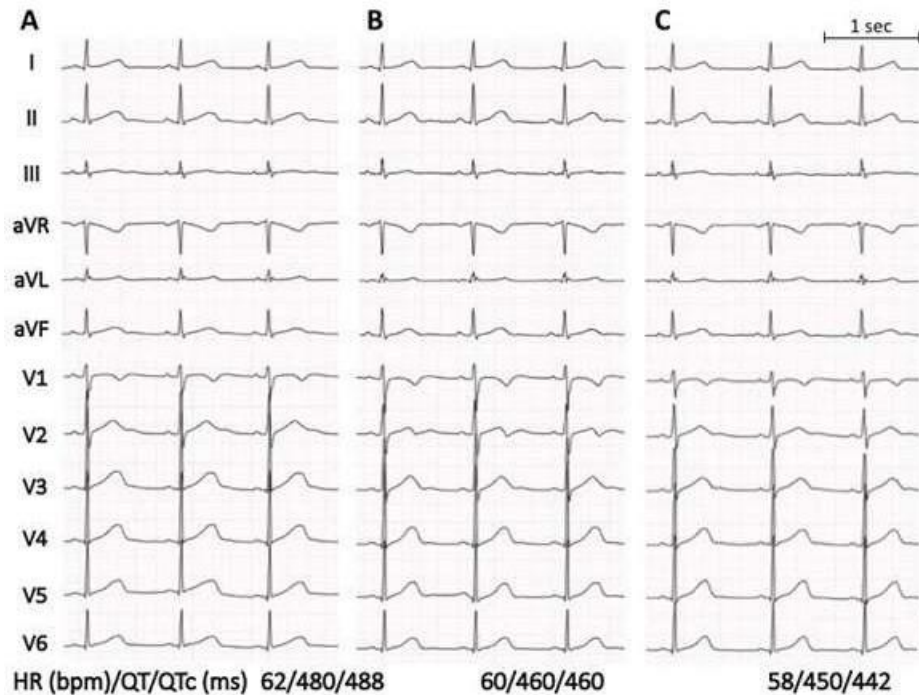


Figure 4. Twelve-lead electrocardiograms after daily oral administration of A) 5, B) 7.5, and C) 10 mg carvedilol.

5. Discussion

This report describes a case of recurrent episodes of syncope that persisted 8 years. When initial 12-lead ECG findings were obtained, the physician did not evaluate data carefully. Instead, the physician relied on an automated ECG diagnosis that was obtained using ECG analysis software. After the QT interval in the patient's 12-lead ECG was first misinterpreted via an automated ECG diagnosis, no physicians recommended a repeat ECG examination or reviewed prior findings, despite the recurrence of syncope episodes. Cardiac syncope is the second most common type of syncope [1], and arrhythmias, including TdP, are its most common cause [2,3]. Moreover, patients with cardiac syncope have the highest risk of recurrence and are at increased risk of death from any cause related to syncope [1]. ECG facilitates the diagnosis of cardiac syncope and improves the prognosis of patients. Therefore, to ensure an accurate diagnosis and determine the cause of syncope, multiple ECG examinations and careful analysis of results are crucial [2]. Automated ECG diagnosis benefits physicians because it reduces the effort needed to evaluate ECG findings and allows physicians to immediately use findings in the clinic. The automated ECG diagnoses are widely utilized in medical practices with non-expert physicians and medical staff [4]. However, automated ECG diagnoses are not always correct. In particular, QT prolongation is underestimated or unreported via diagnostic software [5,6], and measurement differences between algorithms in the determination of QT interval are larger in patients with congenital [7,8] and acquired [9] long QT interval than in healthy subjects. A previous study revealed that automated ECG diagnosis concluded that findings were "normal" in 42.1% of patients with prolonged

QT interval [6]. The phenomenon was observed for algorithms of various manufacturers [10]. From these perspectives, automated ECG diagnosis plus over-reading by physicians offer the accurate diagnosis, and long QT syndrome experts strongly advocate manual measurement [5,11,12]. In the present case, apparent and obvious QT prolongation at 21 years of age (Figure 3A) was missed due to an incorrect automated ECG diagnosis. Twaves in leads I, II, III, aVR, aVF, and V2-V6 had prominent notches, and the second component of the Twaves should have been included in the analysis of the QT interval [11]. The automated ECG diagnosis did not consider the second component of the notched Twave, and instead regarded the endpoint of the first component of the notched Twave as the endpoint of the QT interval. If the physician had self-evaluated ECG findings, they would have noticed the markedly prolonged QT interval and bimodal Twaves, even if the QT interval was inaccurately measured. The patient was administered carvedilol, a non-selective β - and α 1-blocker, from the age of 27, when she was diagnosed with type 2 long QT syndrome. In a prior report, we showed that carvedilol may be used to effectively treat type 2 long QT syndrome [14]. It was suggested that α 1-adrenergic stimulation acutely reduces Kv 11.1 channel activity via the membrane PIP2 pathway [15]. Acute α 1-adrenoceptor-mediated reduction in I_{Kr} at lower heart rate would act additionally to prolong action potential durations and may enhance inward current through Na/Ca exchanger. After the administration of carvedilol, the patient had no episodes of syncope and her QT interval at rest shortened considerably.

6. Conclusions

ECG is an essential method that may be used in the examination of

patients with recurrent syncope. Moreover, all physicians should confirm ECG with their own eyes if there is QT prolongation and not rely exclusively on automated ECG diagnosis.

Zankov DP, Yoshida H, Tsuji K, Tsuji K, Toyoda F, Ding WG, et al. Adrenergic regulation of the rapid component of delayed rectifier K⁺ current: Implications for arrhythmogenesis in LQT2 patients. *Heart Rhythm* 2009; 6(7): 1038-104

References

1. Soteriades ES, Evans JC, Larson MG, Chen MH, Chen L, Benjamin EJ, et al. Incidence and prognosis of syncope. *N Engl J Med*. 2002;347(12):878-885.
2. Priori SG, Wilde AA, Horie M, Cho Y, Behr ER, Berul C, Blom N, et al. HRS/EHRA/APHRS expert consensus statement on the diagnosis and management of patients with inherited primary arrhythmia syndromes. *J Arrhythm* 2014; 30: 1-28.
3. Saklani P, Krahn A, Klein G. Syncope. *Circulation*. 2013;127(12):1330-9.
4. Katoh T, Yashima M, Takahashi N, Watanabe E, Ikeda T, Kasama-ki Y, et al. Expert consensus document on automated diagnosis of the electrocardiogram: The task force on automated diagnosis of the electrocardiogram in Japan. Part 1: Nomenclature for diagnosis and abnormal findings. *J Arrhythm*. 2021; 37: 871-876.
5. Indraratna P, Tardo D, Delves M, Szirt R, Ng B. Measurement and Management of QT Interval Prolongation for General Physicians. *J Gen Intern Med*. 2020; 35(3): 865-873.
6. Garg A, Lehmann MH. Prolonged QT interval diagnosis suppression by a widely used computerized ECG analysis system. *Circ Arrhythm Electrophysiol*. 2013; 6(1): 76-83.
7. Kligfield P, Badilini F, Denjoy I, Babaeizadeh S, Clarke E, DeBie J, et al. Comparison of automated interval measurements by widely used algorithms in digital electrocardiographs. *Am Heart J*. 2018;200: 1-10.
8. Miller MD, Porter Cb, Ackerman MJ. Diagnostic accuracy of screening electrocardiograms in long QT syndrome I. *Pediatrics*. 2001; 108(1) :8-12.
9. Talebi S, Azhir A, Zuber S, Soman S, Visco F, Totoum-Tangho H, et al. Underestimated and unreported prolonged QTc by automated ECG analysis in patients on methadone: can we rely on computer reading? *Acta Cardiol*. 2015; 70(2): 211-216.
10. Schläpfer J, Wellens HJ. Computer-Interpreted Electrocardiograms: Benefits and Limitations. *J Am Coll Cardiol*. 2017; 70(9): 1183-1192.
11. Vink AS, Neumann B, Lieve KV, Sinner MF, Hofman N, El Kadi S, et al. Determination and Interpretation of the QT Interval. *Circulation*. 2018; 138(21): 2345-2358.
12. Postema PG, Wilde AA. The measurement of the QT interval. *Curr Cardiol Rev*. 2014; 10(3): 287-294.
13. Postema PG, De Jong JS, Van der Bilt IA, Wilde AA. Accurate electrocardiographic assessment of the QT interval: teach the tangent. *Heart Rhythm*. 2008; 5(7): 1015-1018.
14. Kimura H, Mizusawa Y, Itoh H, Miyamoto A, Kawamura M, Kawaguchi T, et al. Carvedilol, a non-selective β -with α 1-blocker, effective in long QT syndrome type 2. *J Arrhythm* 2011; 27: 324-331.
- 15.