

Pelvic Solitary Fibrous Tumor

Farré SP, Ventura BM* and Román MP

Section of Colon and Rectal Surgery, Department of Surgery. Hospital del Mar, Barcelona, Spain

*Corresponding author:

Blanca Montcusí Ventura,
Section of Colon and Rectal Surgery, Department
of Surgery, Hospital del Mar, Barcelona, Spain,
E-mail: blancamontcusi@gmail.com

Received: 01 Sep 2021

Accepted: 18 Sep 2021

Published: 23 Sep 2021

Copyright:

©2021 Ventura BM. This is an open access article distributed under the terms of the Creative Commons Attribution License, which permits unrestricted use, distribution, and build upon your work non-commercially.

Citation:

Ventura BM, Pelvic Solitary Fibrous Tumor. Ann Clin Med Case Rep. 2021; V7(9): 1-2

Keywords:

Solitary fibrous tumor; Embolization; Resection

1. Abstract

1.1. Introduction: Solitary fibrous tumor is an extremely rare mesenchymal neoplasia divided into pleural and extrapleural form, the latter being considered uncommon.

1.2. Presentation of Case: We report a case of a woman suffering a pelvic solitary fibrous tumor originated in the S1 nerve root, who underwent selective embolization of the left hypogastric artery and surgical excision.

1.3. Discussion: Solitary fibrous tumor is takes place in adults, presented as an hypervascularised mass which compresses adjacent structures. Histological confirmation with immunohistochemistry is required for diagnosis. Preoperative embolization facilitates surgery in most cases, and radiation should be considered. Complete resection has a good prognosis.

1.4. Conclusion: We describe a patient with a pelvic solitary fibrous tumor, which is a rare mesenchymal neoplasia.

2. Introduction

We report a woman suffering a pelvic SFT, who underwent preoperative embolization and successful surgical excision, with no recurrence after 24-month follow-up. The importance of this report is that SFT is an extremely rare mesenchymal neoplasia.

3. Presentation of Case

A 48-year-old woman with no medical history was referred to evaluate and treat a pelvic mass found during a gynaecological examination. CT and MRI reported a well defined and hypervascularized an extraperitoneal pelvic tumor placed on the left side, adjacent to the hypogastric vessels. The mass, which measured 8.3 x 6 cm, was causing uterine and rectal medial displacement

and extended towards left S1 foraminal, without affecting the bone (Figure 1) [1]. Fine needle puncture-aspiration showed predominance of spindle-shaped cells with mild atypia and isolated mitosis, compatible with SFT. The patient underwent selective embolization of the left hypogastric artery, achieving its complete occlusion (Figure 2). After 48 hours, complete resection of the neoplasia was successfully performed. The mass was originated in the left S1 nerve root and during the surgery, it was released from the adjacent organs which were not infiltrated. In the postoperative period, the patient developed neuropathic pain, disability in left foot dorsiflexion and equinus deformity, as a result of the S1 nerve root resection. The resected specimen measured 71 x 65 x 32 mm (Figure 3), exhibited mesenchymal spindle-like cells proliferation (Figure 4) and included peripheral nerves. Immunohistochemical analysis demonstrated cells positive for CD34, collagen type IV and Ki-67 less than 2%. On this basis, SFT was diagnosed. After 24-month follow-up, no recurrence has been found and neurological sequelae has significantly improved with rehabilitation.

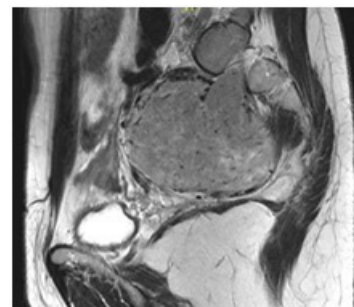


Figure 1: Coronal MRI with the pelvic tumor causing uterine and rectal displacement and extended towards left S1 foraminal.

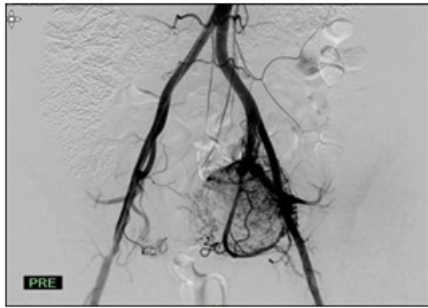


Figure 2: Angiography of the iliac arteries revealing the tumor supplies by the left hypogastric artery.

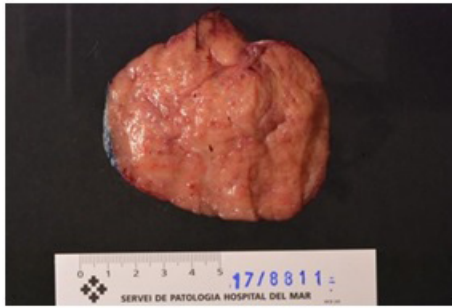

Figure 3: The resected tumor measuring 71 x 65 x 32 mm.

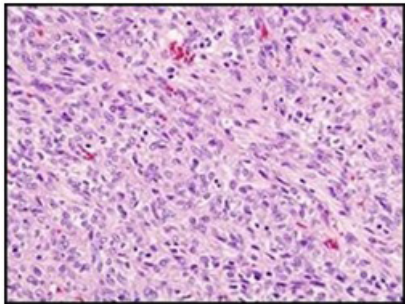


Figure 4: Histologic illustration of the tumor with mesenchymal spindle-like cells proliferation.

4. Discussion

SFT is a rare neoplasia arising from mesenchymal cells. Although it can be found in any body sites, this tumor commonly affects the retroperitoneum and lower extremities. SFT can arise at any age; however, it typically takes place in adults from 60 to 80 years, with a similar male-to-female ratio. The usual presentation is a solid, well-defined and hypervascularised mass. Symptoms are related to the compression of adjacent structures. Diagnosis requires histological confirmation, which shows an appreciable number of vascular elements surrounded by spindle-like cells and collagen bands, with hypercellular and hypocellular keloid-like areas. Conventional immunohistochemical markers of SFTs include CD34, CD99, Bcl-2 and vimentin. Surgical excision is the treatment of choice and preoperative embolization should be considered due to the high risk of intraoperative bleeding. There is no evidence to suggest that adjuvant chemotherapy or radiotherapy would be beneficial; nevertheless, adjuvant radiation should be considered if histological examination is consistent with malignant neoplasia. On one hand, complete resection has a good prognosis with <http://acmcaseports.com/>

80% five-year and 70% 10-year survival rate. On the other hand, 15-20% of patients present local recurrences and metastasis (lung, bone and liver) even 10 years after surgery, therefore a long-term follow-up with chest-abdomen-pelvis CT examination should be performed [2].

5. Conclusion

SFT is a rare mesenchymal neoplasia. In this case report, we describe a patient with a pelvic SFT who underwent preoperative embolization to facilitate surgery, with no recurrence after 24-month follow-up [3,4].

6. Acknowledgements

The authors wish to thank the patient who kindly gave consent for the case to be presented in this manuscript, and staff of our Department of Surgery for their continuous support and guidance.

7. Funding

This research did not receive any specific grant from funding agencies in the public, commercial, or not-for-profit sectors.

References

1. DeVito N, Henderson E, Han G, Reed D, Bui MM, Lavey R, et al. Clinical Characteristics and Outcomes for Solitary Fibrous Tumor (SFT): A Single Center Experience. *PLOS ONE* 2015; 10(10): e0140362. [dx.doi.org/10.1371/journal.pone.0140362](https://doi.org/10.1371/journal.pone.0140362).
2. Yokoyama Y, Hata K, Kanazawa T, Yamaguchi H, Ishihara S, Sunami E, et al. Giant solitary fibrous tumor of the pelvis successfully treated with preoperative embolization and surgical resection: a case report. *World J Surg Oncol* 2015; 13(1): 164. [dx.doi.org/10.1186/s12957-015-0578-6](https://doi.org/10.1186/s12957-015-0578-6).
3. García-Amador C, De La Plaza R, Ramia JM, Guerra M, Arteaga V, Valenzuela J. Pelvic Solitary Fibrous Tumor. *J Gastrointest Surg*. 2018; 22(8): 1448-1449. [dx.doi.org/10.1007/s11605-017-3651-3](https://doi.org/10.1007/s11605-017-3651-3).
4. Bruzzone A, Varaldo M, Ferrarazzo L, Tunesi G, Mencoboni M. Solitary fibrous tumor. *Rare Tumors* 2010;2(4):183-185. [dx.doi.org/10.4081/rt.2010.e64](https://doi.org/10.4081/rt.2010.e64).