

## Genital Hair Tourniquet Syndrome in A 5-Year Old Girl

Minodier P\*, Cohen-Boulakia R, Aguesse C, Fruscione S and Urbina D

Departement of Pediatric emergency, Hôpital Nord, Chemin des Bourrelly, 13015 Marseille, France

### \*Corresponding author:

Minodier Philippe,  
Departement of Pediatric emergency,  
Hôpital Nord, Chemin des Bourrelly,  
13015 Marseille, France,  
Tel: 33 4 91 96 88 13,  
E-mail: [philippe.minodier@ap-hm.fr](mailto:philippe.minodier@ap-hm.fr)

Received: 02 Dec 2020

Accepted: 18 Dec 2020

Published: 21 Dec 2020

### Copyright:

©2020 Minodier P et al., This is an open access article distributed under the terms of the Creative Commons Attribution License, which permits unrestricted use, distribution, and build upon your work non-commercially.

### Citation:

Minodier P. Genital Hair Tourniquet Syndrome in A 5-Year Old Girl. *Annals of Clinical and Medical Case Reports*. 2020; V5(5): 1-2.

### 1. Abstract

A swollen and painful clitoris was noticed by the parents of a 5 year-old-girl. A hair tourniquet was found at the base of the clitoris and mechanically removed in the hospital. Genital hair thread tourniquet syndrome is a rare entity, which can be misdiagnosed and can lead to genital complications if the treatment is delayed.

### 2. Clinical Image

A 5 year-old girl was admitted in our pediatric emergency ward for a swollen and painful clitoris noticed when waking up. No necrosis was observed.

A hair tourniquet was found at the base of the clitoris. After mechanical removal of the hair, the edema of the clitoris disappeared in one hour.

Hair Thread Tourniquet Syndrome (HTTS) is caused by an encircled hair or fiber around an appendage. It is frequently observed around toes and fingers in infants and toddlers. Genital location of HTTS is rarer. Thirty four cases have been recently reviewed in girls aged 6 months to 14 years (most of them were older than 4 years) [1]. Pain and swelling were the main complaints, and genital exams showed congestion, edema and/or abnormal coloration (from redness to cyanosis or necrosis) of the clitoris (44%), labia minora (44%), labia majora (9%) or mons pubis (3%). Penile strangulation can also be observed in boys [2], leading to excoriations, edema, dysuria, discoloration of the glans or section of urethra. Although HTTS is considered to be accidental, some older

boys have reported to have themselves tied a thread around the penis to control bed wetting. The mechanism of tourniquet is thought to be due to the entangling of a wet and elastic hair that dries later, thus shortening and becoming constricting [3].

If not diagnosed, HTTS can lead to prolonged pain, genital necrosis or auto-amputation. Mechanical removing under sedation of the constricting hair is required as soon as possible. Depilatory creams used in finger/toe HTTS [4] have an irritant effect on genital mucous membranes. The removal of the hair/thread can be difficult because of its small diameter and the surrounding edema, especially in the youngest children or in prolonged constriction's situations.

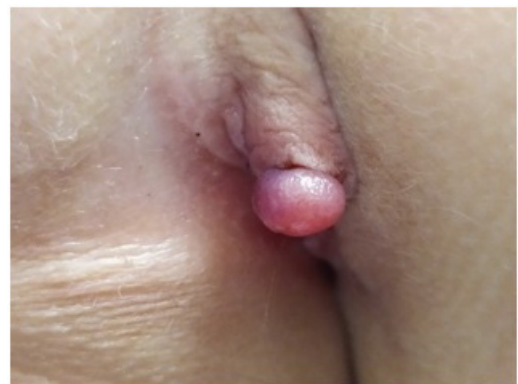


Figure 1: Genital HTTS

## References

1. Diaz-Morales O, Martinez-Pajares JD, Ramos-Diaz JC, Lopez JGDA, Trigo-Moreno J, et al. Genital hair-thread tourniquet syndrome. *J Pediatr Adolesc Gynecol* 2020 Jun 11; S1083-3188(20): 30235-7. doi: 10.1016/j.jpag.2020.05.009.
2. Qamar J, Kasmi Z, Dilawar D, Nazir Z. Penile strangulation injury in children - Reconstructive procedure and outcome. *J Pediatr Surg.* 2020; 55: 1165-8.
3. Gottlieb M, Holladay D, Spearman D. Current approach to the evaluation and management of hair-thread tourniquets. *Pediatr Emerg Care.* 2019; 35(5): 377-9.
4. Alruwaili N, Alshehri HA, Halimeh B. Hair tourniquet syndrome: Successful management with a painless technique. *Int J Pediatr Adolesc Med.* 2015; 2: 34-7.