

Bruises as First Manifestation of Cutaneous Angiosarcoma

Ilaria T^{1,2*}, Gianfranco B², Francesco C³, Michele P^{3,4}, Giuseppina N² and Aurora P^{1,2}

¹Department of Dermatology Unit, Department of Health Sciences (DISSAL), University of Genoa, Genoa, Italy

²Department of Dermatology Unit, Ospedale Policlinico San Martino IRCCS, Genoa, Italy

³Department of Pathology Unit, Ospedale Policlinico San Martino IRCCS, Genoa, Italy

⁴Department of Surgical Sciences and Integrated Diagnostics (DISC), University of Genoa, Genoa, Italy

Volume 4 Issue 8- 2020

Received Date: 28 July 2020

Accepted Date: 08 Aug 2020

Published Date: 11 Aug 2020

2. Key words

Bruises; Cutaneous angiosarcoma

1. Abstract

Cutaneous angiosarcoma is a soft tissue sarcoma that presents as a violaceous plaque, resembling a persistent bruise on the head and neck. The hematoma-like lesions are pitfalls that could be the first spy of malignant vascular tumors. The low survival rates of cutaneous angiosarcoma require a recognition as early as possible. We report a case of misdiagnosed cutaneous angiosarcoma of the head, which developed after a car crash and that, was firstly diagnosed as bruise.

3. Introduction

Bruises could be pitfalls especially when they are long-lasting and unresponsive to traditional therapy. They could be the first spy of malignant vascular tumors like cutaneous angiosarcoma and Kaposi sarcoma. A detailed anamnesis and an evaluation of risk factors are important to direct the diagnosis. We report a case of misdiagnosed cutaneous angiosarcoma of the head which developed after a car crash and was firstly diagnosed as bruises.

4. Case presentation

A 86-year-old man presented to the Dermatology Department with a 2-month history of new-onset violaceous erythematous-edematous lesion on the top of the head. This appeared concurrently with multiple break cracked ribs during a car crash and it was diagnosed, in the first instance, as an ecchymotic bruising. He had a history of melanoma pT1a on the back 15 years ago and a history of melanoma pT2b overlying left shoulder blade 5 years ago with negative sentinel lymph node. On examination, the patient showed an erythematous-violaceous indurated ecchymotic plaque with violaceous nodules and multiple ulcerations on his head (Figure 1A). A skin incisional biopsy was executed and the histopathological examination showed irregular dissecting vascular proliferation through the dermis. Atypical endothelial cells surrounded vascular areas and they sometimes aggregated themselves (Figure 1B). Since patient's history, we suspected a Kaposi sarcoma and a metastatic melanoma. Immunohistochemistry stain were performed resulting negative for Human herpesvirus 8, pS100, HMB45 and melan-A ruling out this diagnoses. Positive CD31+ with high percentage of Ki67 were diagnostic of cutaneous angiosarcoma (Figure 1C).

Due to patient's disease extension and poor performance status, short radiotherapy cycle was performed as palliative therapy. He was transitioned to home hospice where he died one month later.

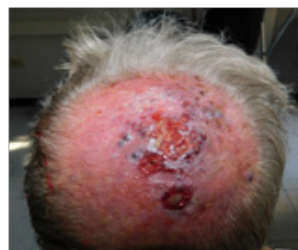

Figure 1: Hard violaceous nodules over a erythematous-violaceous indurated ecchymotic plaque with ulcerations on the top of the head.

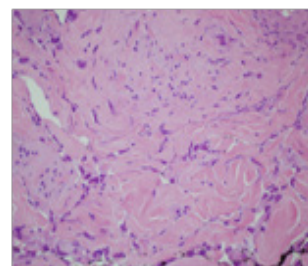


Figure 2: Dissecting vascular areas surrounded by atypical endothelial cells. (H&E; 60x)

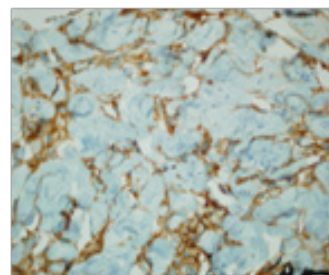


Figure 3: Immunohistochemistry stain positive for CD31+. (CD31; 60x)

*Corresponding Author (s): Ilaria TRAVE, Dermatology Unit, Department of Health Sciences (DISSAL), University of Genoa, Ospedale Policlinico San Martino IRCCS, Via Pastore 1, 16132 Genoa, Italy. Tel. +390105555750, Fax +390105556509, E-mail: ilaria.trave@gmail.com

5. Discussion

We describe a case of a patient with persistent bruises on the head following a car crash. Long-term bruises evolving in nodular lesions could be suspect for malignant vascular tumors, such as cutaneous angiosarcoma and Kaposi sarcoma. Cutaneous angiosarcoma accounting for 1% of soft tissue sarcomas, fourth for frequency among cutaneous sarcomas [1]. Average age of diagnosis is 73 years, with a slight male white patient predominance [2]. The most important risk factor of cutaneous angiosarcoma is ultraviolet light with higher risk in patients with genetic susceptibility. Cutaneous angiosarcoma is usually an idiopathic primitive form that occurs more frequently on the face and scalp (angiosarcoma of Wilson Jones). Other two forms of angiosarcoma are known: chronic lymphedema-associated cutaneous angiosarcoma (Stewart-Treves syndrome) arising secondary to lymphedema following axillary lymphnode dissection and the post irradiation cutaneous angiosarcoma arising in areas previously treated for solid tumor malignancies like breast cancer. A violaceous plaque, resembling a persistent bruise on the head and neck is the most typical clinical presentation. Usually it can lead to rapid growth, ulceration, localized hemorrhage or invasion into adjacent structures due to its aggressive nature. Nodular lesion is significantly more common in cutaneous angiosarcoma on the scalp [3]. Histopathology of cutaneous angiosarcoma includes weird endothelial cells arranged in irregular, disarrayed vascular lines or sinusoids shifting normal, regularly oriented collagen within the dermis. Immunohistochemical expression of CD31, CD34, D2-40, and VEGFR3 can help to differentiate cutaneous angiosarcoma from nonendothelial neoplasms. Secondary forms of cutaneous angiosarcoma can present MYC expression [2]. The differential diagnosis of hematoma-like lesions include vascular tumor such as Kaposi sarcoma. It could be differentiated by cutaneous angiosarcoma by histology and a positive immunohistochemistry for Human herpesvirus 8. In addition, since our patient have removed two melanomas, the diagnosis of metastasis should be excluded by histology and immunohistochemistry. Five-year survival of cutaneous angiosarcoma is approximately 50%, with lowest survival rates among individuals with head and neck lesions [1]. Treatments of cutaneous angiosarcoma include surgery, radiation therapy, and systemic chemotherapy. Wide local excision with negative margins is suggested, because is associated with improved survival. The management of large cutaneous angiosarcoma required multimodal strategies (eg, excision plus radiation treatment). Tumors larger 5 cm are associated with worse outcomes and they may benefit from multimodal treatment with taxanes, first-line treatment, plus radiation. In addition, Eribulin mesylate showed a promising response rate in patients previously treated with taxane [4]. Emerged immunotherapies (eg pembrolizumab) and electrochemotherapy [5] are also in assessment. We describe a case of cutaneous angiosarcoma, a

tumor with low survival rate recognized rarely in early stage. We suggest being careful with long-lasting ecchymotic lesions, they require a biopsy to speed up the diagnosis of cutaneous neoplasms as angiosarcoma.

References

1. Requena C, Alsina M, Morgado-Carrasco D, et al. Kaposi Sarcoma and Cutaneous Angiosarcoma: Guidelines for Diagnosis and Treatment. *Actas Dermosifiliogr*. 2018; 109: 878-887.
2. Bhatt MD, Nambudiri VE. Cutaneous Sarcomas. *Hematol Oncol Clin North Am*. 2019; 33:87-101.
3. Moon IJ, Kim YJ, Won CH, et al. Clinicopathological and survival analyses of primary cutaneous angiosarcoma in an Asian population: prognostic value of the clinical features of skin lesions. *Int J Dermatol*. 2020; 59: 582-589.
4. Fujisawa Y, Fujimura T, Matsushita S, et al. The efficacy of eribulin mesylate for patients with cutaneous angiosarcoma previously treated with taxane: a multi-center, prospective, observational study [published online ahead of print, 2020 Mar 20]. *Br J Dermatol*. 2020; 10.1111/bjd.19042.
5. Campana LG, Kis E, Bottyán K, et al. Electrochemotherapy for advanced cutaneous angiosarcoma: A European register-based cohort study from the International Network for Sharing Practices of electrochemotherapy (InspECT). *Int J Surg*. 2019; 7 2: 34-42.