

## Abdominal Tumor Case Report

Daniela R\*

Department of Medicine, University of Medicine and Pharmacy "Victor Babes" Timisoara Romania

Volume 4 Issue 6- 2020

Received Date: 02 July 2020

Accepted Date: 14 July 2020

Published Date: 17 July 2020

### 1. Abstract

1.1. Aim: The ovarian teratoma is a tumor formed by pluripotent germinal cells, benign or malignant. In Surgical Clinic 1 there have been operated a lot of giant abdominal tumors.

1.2. Clinical case: a 30 years old female patient is hospitalized with abdominal pain, tenesmes and polakiury. Ambulatory exams showed a large dimensions abdominal tumor. Following surgery, three anaxiale bilateral tumors, (18 – 35 cm) were completely removed.

1.3. Results: histopathological diagnosis: bilateral ovarian mature cystic teratoma. Post-operative evolution is favorable, the outcome in 8 days. The treatment of the teratoma is surgical with complete removed of the tumor. The procedure is easily performed in the case of the non-invasive, small - tumors and difficult in large, invasive tumors.

#### 1.4. Conclusions:

1. The voluminous ovarian tumors still create diagnostic and surgical removed difficulties.
2. The certitude diagnosis is histopathological, surgical treatment is different, depending on histological diagnosis, dimensions and tumor extension.
3. The bilateral localization it causes female infertility.

## 2. Background

The ovarian teratoma is a pluripotent germinal cells tumor, benign or malignant (immature forms), usually found in ovaries. It predominates in young female patients during their fertile period, found mainly unilaterally and presenting a multilayered origin: ectodermal, endodermal or mesodermal [1].

The tumor may reach huge dimensions. The main localization of the teratoma is the sacral coccygeal region (40% cases) respectively ovarian region (37%) [1].

In the medical literature there have also been reported other rare localizations of teratomas, which can be found at all body levels. Consequently, cases of different localizations of teratomas have been reported: cerebral, pharyngeal, mouth region, nasal, cervical, thyroid, mediastinal, thymus, pericardial, pulmonary, diaphragmatic, gastric, pancreatic, mesenteric, sigmoid, right colon, renal, adrenal and retroperitoneal [2-7, 11-14, 16, 18, 22-24].

The incidence of teratoma is approximately one in every 30.000-40.000 newborn female babies [2, 3]. A statistical study carried out in China, on 4.500.000 new born showed an incidence of 0.53 cases in 10.000 childbirths, 3 times more frequently in female babies [4].

## 3. Material and Method

Female, 30 years old, obese, hirsute, was hospitalized in Surgical

Clinic no.1, County Emergency Hospital Timisoara.

Clinically, patient complained of persistent pelvic pain, metrorrhagia and sometimes acute abdominal pain.

Imagistic was based mainly on ultrasound and Doppler ultrasound examination, completed with computer tomography and magnetic resonance imaging. These examinations may provide precise data regarding the tumor topography, possible surrounding invasion, dimensions, useful information for the proper surgical approach.

Simple radiography shows frequently areas of disseminating calcifications into the tumor area.

Barium enema and urography offer helpful information in the case of external compression or invasion on the surrounding organs by the tumor.

After a short preoperative preparation the abdominal tumor was removed.

In the case of a giant mediastinal teratoma have been highlighted the level of CA 125 and CA 19-9 (19), as tumor markers [18].

In this case the tumor markers levels were within normal limits.

Pelvic CT: tumor mass with mixed density (parenchymal – fatty), presenting internal calcifications, poorly - enhancing, with the suspicion of ovarian teratoma. Indication of MRI.

\*Corresponding Author (s): Daniela Radu, Department of Medicine, University of Medicine and Pharmacy "Victor Babes" Timisoara Romania. E-mail: daniela\_radu@hotmail.com

Citation: Daniela R, Abdominal Tumor Case Report. Annals of Clinical and Medical Case Reports. 2020; 4(6): 1-5.

MRI: confirms the presence of a well encapsulated tumor formation, with most likely ovarian origin, presenting inhomogeneous signal with fat suppression (fat component), central T1 and T2 signal (bony structure) and T1 and T2 (bleeding areas), suggesting an ovarian teratoma.

Sometimes, the diagnosis may be suggested by using cytological criteria. Thus, in ovarian teratomas, apparently not presenting any continuity solution, the peritoneal lavage analysis may present hair and squamous cells, surrounded by inflammatory cells [20]. A systematization of the ultrastructural characters of the peritoneal lavage cells (in the ovarian teratoma) includes: an increased ratio nucleus / cytoplasm; roundish – oval nuclei with homogenous distributed chromatin; 1-2 nucleoli; insufficient cytoplasm [20].

We must recognize and accept the limits of imagistics in establishing a pre-operative correct diagnostic. Unfortunately in many cases it is established only intra or even post-operatory, based on the histopathological exam.

Subsequent to the surgical operation carried out in 05.12.2019 (classical median laparotomy) 3 gigantic bilateral ovarian tumors were removed (1 follicular cyst and 2 dermoid cysts) (Figure 2-9).

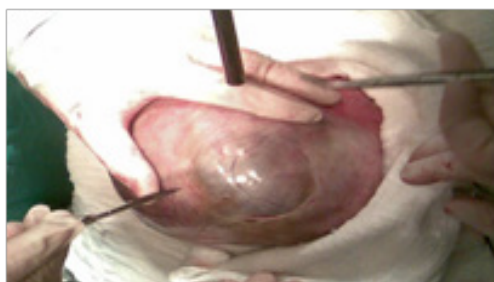

Figure 1: intraoperative image

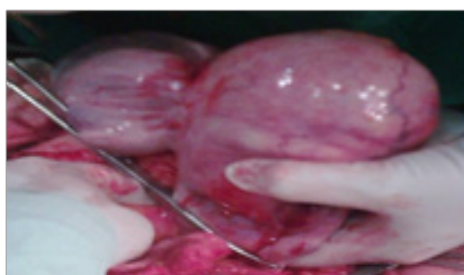


Figure 2: Intraoperative image: 2 dermoid cysts

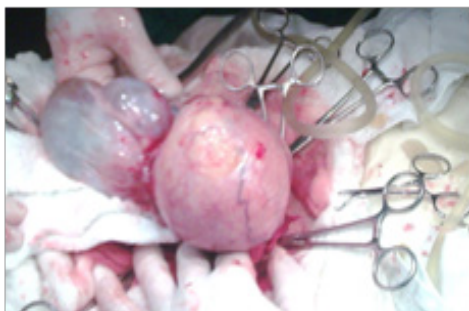


Figure 3: Intraoperative image:follicular and dermoid cyst

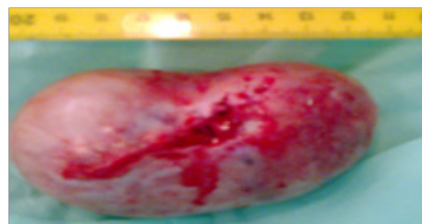

Figure 4: Postoperative image of dermoid cyst

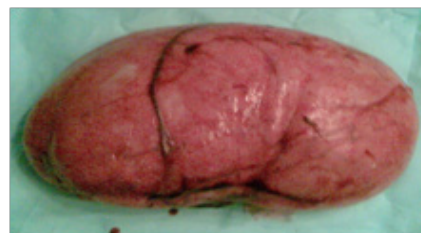

Figure 5: Postoperative image of dermoid cyst

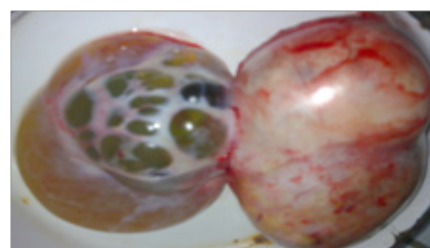


Figure 6: Postoperative image:dermoid cyst (left) and follicular cyst (right)

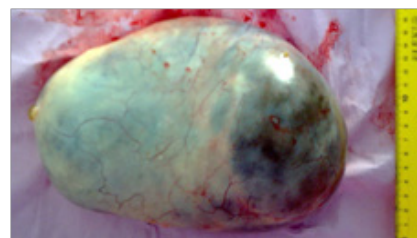


Figure 7: Postoperative image:dermoid cyst

#### 4. Results

The histopathological exam carried out on resection pieces showed a specific macroscopic aspect :left ovary with cystic transformation, measuring 14 / 6 / 2,5 cm, presenting pinkish whitish external surface, yellowish areas; when sectioned, the large dimension cystic cavity was occupied by a creamy yellowish material containing hair follicles and other cystic cavities occupied by a yellowish gelatinous material (Figure 8,9).

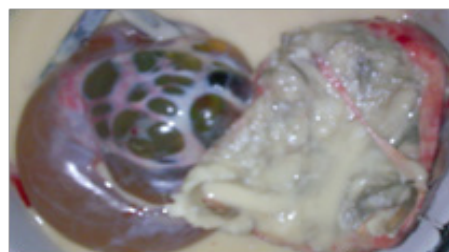


Figure 8: Postoperative image:dermoid cyst contents (left) and follicular cyst (right)

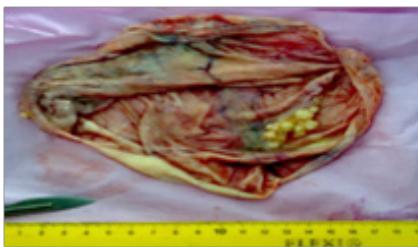


Figure 9: Postoperative image:inner wall of the dermoid cyst

The right ovary also presented cystic transformation, measuring 7,5 / 5,5 / 0,5 cm , presenting a whitish, grayish, pinkish external wall, the internal wall being extensively covered with yellowish creamy material, presenting hair follicles.

The microscopic examination after inclusion in paraffin: ovary presenting hemorrhagic yellow body, follicular cysts and mature tissues dermis, epidermal (including ovarian glands), nervous tissue and adipose tissue with lipid-granuloma aspect, cystic degenerations, multinucleated giant cells and calcification foci, with histiocytes and macrophages areas presenting hemosiderin pigment (Figure 10).

The favorable postoperative evolution allowed the discharge after 8 days.

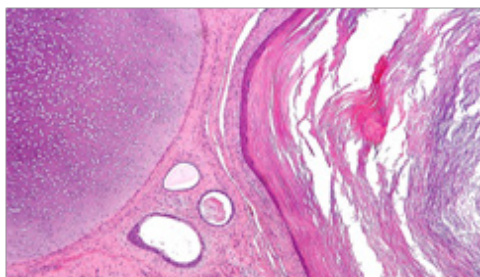


Figure 10: Dermoid cyst (hematoxylin-eosin stain)

## 5. Discussions

At present there is a consensus regarding the genetic determinism in teratoma appearance. Thus, different theories stated: 7q chromosome deletion, associated with partial trisomy 2p; 22 and 1 p chromosome anomaly; 8p chromosome anomaly; partial duplication of the long arm of the 1<sup>st</sup> chromosome; deletions and mutations of the h SNF5 / INI gene. The increase of the mutant p53 protein activity is associated with increased risk of malignancy. Cytogenetic pattern variations described sustain the hypothesis that different genetic pathways may lead to the characteristic phenotype of tumor type [5]. Other genetic studies showed the common clonal origin of the teratoma and malign tumors originating from the germinal cells of the testicle [6]. The specific element of teratoma, explaining the particular scientific interest is represented by the variety of the pathological changes. These tumors may sometimes contain tissues structures resembling to normal organs, with a high organization degree. The medical literature quotes the clinical case of a 25 years old female virgin patient, presenting an ovarian teratoma with a

homunculus inside, with the cephalic extremity, trunk and limbs, correctly arranged antero-posterior, ventro-dorsally and right-left. The tissues study showed structures resembling those found in the brain, eye, ear, tooth, bone, tracheae, and vessels [7]. Other times, the tissues found in a teratoma constitute complex structural organs. In a five day new born female, the sacral – coccygeal teratoma contained 30 cm intestinal loops, presenting proper mesentery inside [8]. Different tissues structures of the teratoma may present malign transformations. Thus, there could be identified: gastro-intestinal adenocarcinoma, lymphoma, scuamous cell carcinoma, sebaceous carcinoma, rabdomiosarcoma, malign melanoma. Beside structural changes, teratomas may also present functional characteristics. The medical literature mentions two secreting teratoma cases: a pelvic teratoma producing rennin, constituting the cause of a severe hypertension in a 17 years old female patient [9] and a somatostatin secreting ovarian teratoma, generating rapid alternation hiper- hipoglicemic crisis in a 54 years old female patient [10].

During the last years, the most spectacular progresses were recorded in the diagnostic and treatment of the fetal teratomas. In specialized centers, they are not exceptional events anymore. Thus, using tridimensional ultrasound, have been diagnosed pre-birth: a sacral – coccygeal teratoma in a 17 month fetus [11] and even a 12 weeks old fetus [12] and also a 17 weeks intra-pericardial teratoma.

The therapeutic attitude is differentiated, depending on the surgical timing:

- Pre-natal surgical treatment. It implies: cystic aspiration, amnioreduction, amniofusion or open resection.
- Combined treatment, pre- and post-natal.

The teratoma treatment must be always a surgical one. All the authors insist on the importance of complete excision, in order to eliminate all risks of recurrence. It may be easier in the case of small – dimensions, non-invasive tumors, but extremely complicated in the case of large dimension tumors, presenting invasive characters [17]. In the case of difficult tumor excision, hemorrhage may lead to serious lesions of pelvic viscera, necessitating sometimes complete resection. The rectal invasion [16] usually does not reach the submucosal and tumor excision must be followed by the recovery of the intestinal wall.

The classic technique described by Krasje, via the sacred bone with the resection of coccyx and the last sacral vertebra, this procedure is indicated in the case of large dimension tumors, the operating area could be cranially enlarged, depending on the particular aspect of the tumor.

The perineal approach is indicated for smaller tumors without a characteristic of invasion.

The abdominal and perineal approach presents the advantage of bipolar approach of the tumor, having constant rapports with the neighboring viscera, so as not to damage them.



In the case of welldefined benign ovarian teratomas presenting reasonable dimensions, the laparoscopic approach is indicated. The round ligament teratoma resection [24] and the thoracoscopy assisted resection of an anterior mediastinum teratoma [25] may also benefit from this modern surgical treatment.

In the case of malign transformation of the tumor, it is necessary to associate complementary oncologic therapy (chemotherapy and irradiation). In all the benign and malign cases there is a possibility of reoccurrence, for this reason the operated patients must be monitored for a period of a few years, using periodic clinical and imaging investigations.

Out of the tumor complication, a paradoxical phenomenon is the teratoma growing syndrome. It consists in the rapid recurrence of the tumor, after chemotherapy, despite the apparent surgical excision, initially completed apparently [22, 23].

## 6. Conclusions

1. Voluminous ovarian tumors are still creating diagnostic and surgical difficulties for removing.
2. The certainty diagnostic is based on the histopathological exam; the surgical treatment depends on the localization, the size and the surrounding tumor extension.
3. Bilateral localization of ovarian tumors may be a cause of female infertility.

## References

1. Guzzetta P, Anderson K, Altman R, Newman K, Eichelberger M, Randolph J. Pediatric Surgery- in Schwartz S, Shires T, Spencer F, Principles of Surgery, McGraw-Hill Book Co, 1989; pag. 1721.
2. Pantanowitz L, Jamieson T, Beavon I. Pathobiology of sacrococcygeal teratomas. [Review][120 refs]. South African Journal of Surgery. 2001; 39:56.
3. Axt-Flidner R, Hendrik HJ, Reinhard H, Ertan AK, Friedrich M, Remberger K, Schmidt W. Prenatal diagnosis of sacrococcygeal teratoma: a review of cases between 1993 and 2000. Clinical & Experimental Obstetrics & Gynecology. 2002; 29: 15.
4. Dai L, Wu Y, Zhu J, Wang Y, Zhou G, Liang J, Miao L. An epidemiological investigation of perinatal teratomas in China. Journal of West China University of Medical Sciences. 2002; 33:111.
5. Wharton SB, Wardle C, Ironside JW, Wallace WH, Royds JA, Hammond DW. Comparative genomic hybridization and pathological findings in atypical teratoid/rhabdoid tumour of the central nervous system. Neuropathology & Applied Neurobiology. 2003; 29: 254.
6. Kernek KM, Ulbright TM, Zhang S, Billings SD, Cummings OW, Henley JD, Michael H, Brunelli M, Martignoni G, Foster RS, Eble JN, Cheng L. Identical allelic losses in mature teratoma and other histologic components of malignant mixed germ cell

tumors of the testis. American Journal of Pathology. 2003; 163: 2477.

7. Kuno N, Kadomatsu K, Nakamura M, Miwa-Fukuchi T, Hirabayashi N, Ishizuka T. Mature ovarian cystic teratoma with a highly differentiated homunculus: a case report. Birth Defects Research. 2004; 70: 40.
8. Aslan A, Karaguzel G, Gelen T, Melikoglu M. Sacrococcygeal teratoma showing organoid differentiation: report of a case. Surgery Today. 2003; 33: 560.
9. Pursell RN, Quinlan PM. Secondary hypertension due to a renin-producing teratoma. American Journal of Hypertension. 2003; 16: 592.
10. Gregersen G, Holst JJ, Trankjaer A, Stadil F, Mogensen AM. Case report: somatostatin producing teratoma, causing rapidly alternating extreme hyperglycemia and hypoglycemia, and ovarian somatostatinoma. Metabolism: Clinical & Experimental. 2002; 51: 1180.
11. Sun DJ, Lee JN, Long CY, Tsai EM. Early diagnosis of fetal sacrococcygeal teratoma: a case report - Kaohsiung Journal of Medical Sciences. 2003; 19: 313.
12. Roman AS, Monteagudo A, Timor-Tritsch I, Rebarber A. First-trimester diagnosis of sacrococcygeal teratoma: the role of three-dimensional ultrasound. Ultrasound in Obstetrics & Gynecology. 2004; 23: 612.
13. Hedrick HL, Flake AW, Crombleholme TM, Howell LJ, Johnson MP, Wilson RD, Adzick NS. Sacrococcygeal teratoma: prenatal assessment, fetal intervention, and outcome. Journal of Pediatric Surgery. 2004; 39: 430.
14. Jouannic JM, Dommergues M, Auber F, Bessis R, Nihoul-Fekete C, Dumez Y. Successful intrauterine shunting of a sacrococcygeal teratoma (SCT) causing fetal bladder obstruction. Prenatal Diagnosis. 2001; 21: 824.
15. Takahashi K, Shinno T, Watanabe Y, Kurioka H, Miyazaki K. Benign teratoma in an 85-year-old woman. Archives of Gynecology & Obstetrics. 2000; 263: 188.
16. Dragomirescu C, Tască C, Ghiga D. Chist vestigial retrorectal la adult. Chirurgia, 1993, XLII: 58 .Engun S., Grosfeld J. - Chapter 67, Pediatric Surgery. În: Sabiston - Textbook of Surgery. Editia a 16-a. WB Saunders Co. 2001; 1510-1511.
17. Priscu AI, Palade R, Neagu S, Vrejoiu G. Dificultăți diagnostice si terapeutice în tumorile paraanorectale disembrioplazice. Chirurgia, 1980; XXIX: 373.
18. Nagata K, Iwasaki Y, Nakanishi M, Natsuhara A, Harada H, Yokomura I, Hashimoto S, Nakagawa M. A case of mediastinal teratoma with elevated serum tumor marker levels. Nihon Kokyuki gakkai Zashi. 2002; 40: 50.

19. Miyake Y, Hirokawa M, Kanahara T, Fujiwara K, Koike H, Manabe T. Diagnostic value of hair shafts and squamous cells in peritoneal washing cytology. *Acta Cytologica*. 2000; 44: 357.
20. Selvaggi SM, Guidos BJ. Immature teratoma of the ovary on fluid cytology. *Diagnostic Cytopathology*. 2001; 25: 411.
21. Andre F, Fizazi K, Culine S, Droz J, Taupin P, Lhomme C, Terrier-Lacombe M, Theodore C. The growing teratoma syndrome: results of therapy and long-term follow-up of 33 patients. *European Journal of Cancer*. 2000; 36: 1389.
22. Eghtesad B, Marsh WJ, Cacciarelli T, Geller D, Reyes J, Jain A, Fontes P, Devera M, Fung J. Liver transplantation for growing teratoma syndrome: report of a case. *Liver Transplantation*. 2003; 9: 1222.
23. De Los Rios JF, Ochoa JG, Mejia JM, Mesa A. Laparoscopic management of teratoma of the round ligament. *Journal of the American Association of Gynecologic Laparoscopists*. 2004; 11: 265.
24. Cheng YJ, Huang MF, Tsai KB. Video-assisted thoracoscopic management of an anterior mediastinal teratoma: report of a case. *Surgery Today*. 2000; 30: 1019.